SoFFœt
Société Française de Fœtopathologie

ASSISTANCE PUBLIQUE HÔPITAUX DE PARIS

Necker ENFANTS MALADES
HÔPITAL UNIVERSITAIRE

Fetal presentation of Verheij syndrome, a spliceosomopathy

Marie Carteau, Nathalie Roux, Philippe Roth, Julien Stirnemann, Pascale Sonigo, Jeanne Amiel, Tania Attié-Bitach

Journées BEST OF SOFFOET 15/10/2021

Clinical History

- 23 years old, caucasian, G2P0 + abortion, unrelated couple

- Ultrasound 29WG

IUGR, most on abdominal perimeter
Dysplasia of the left ear, pre auricular tag on the left ear, right clubfoot

- Genetic:

CMA 400kb normal
Prenatal Exome Sequencing: variation *PUF60* (Verheij syndrome)
PUF60 gene, NM_078480.2: c.449_457del, p(Ala50_Phe152del

- Ultrasound 32 WG

Worsen IUGR

- MRI 32 WG

Normal brain
Left ear aplasia, dysmorphic left auricle, pre auricular tag, left external auditory canal aplasia
Normal right ear

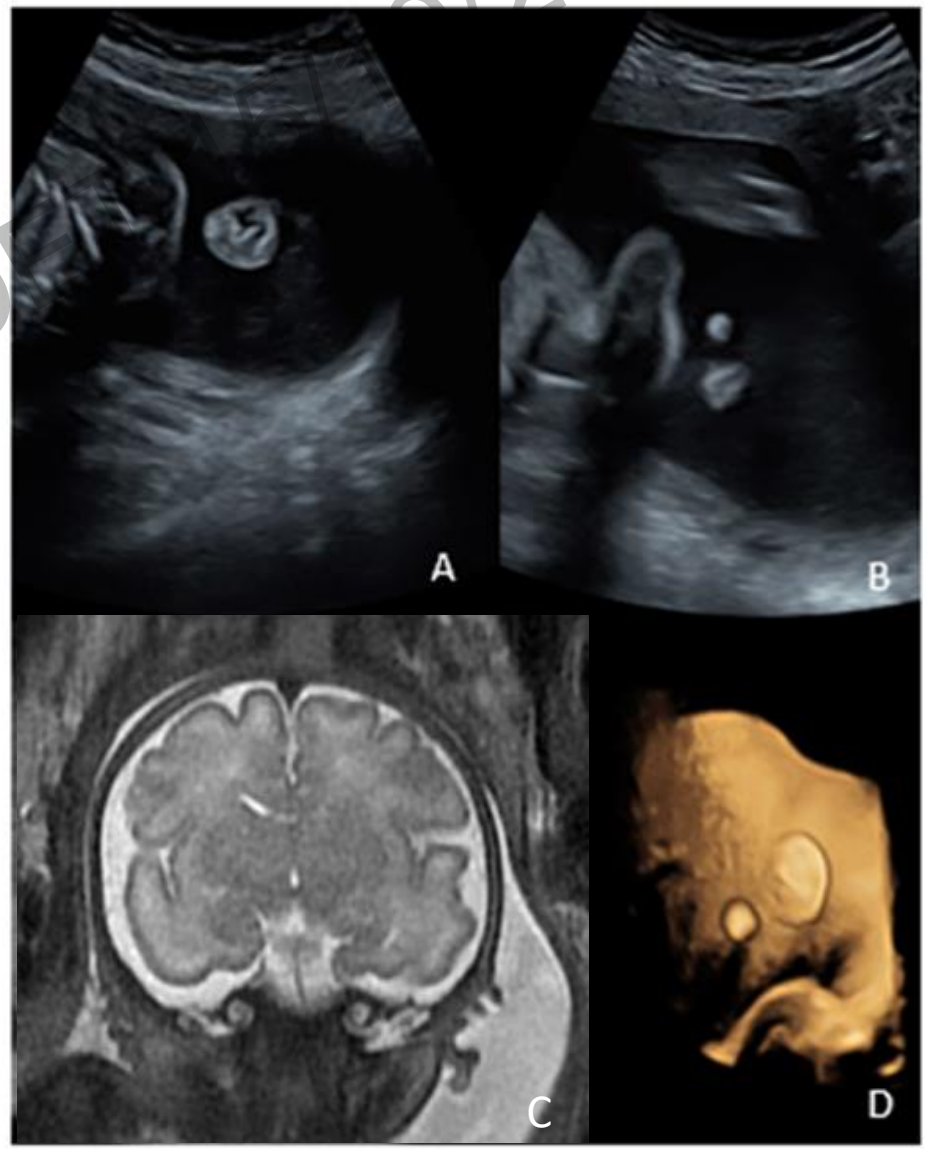

Journées BEST OF SOFFOR 2021

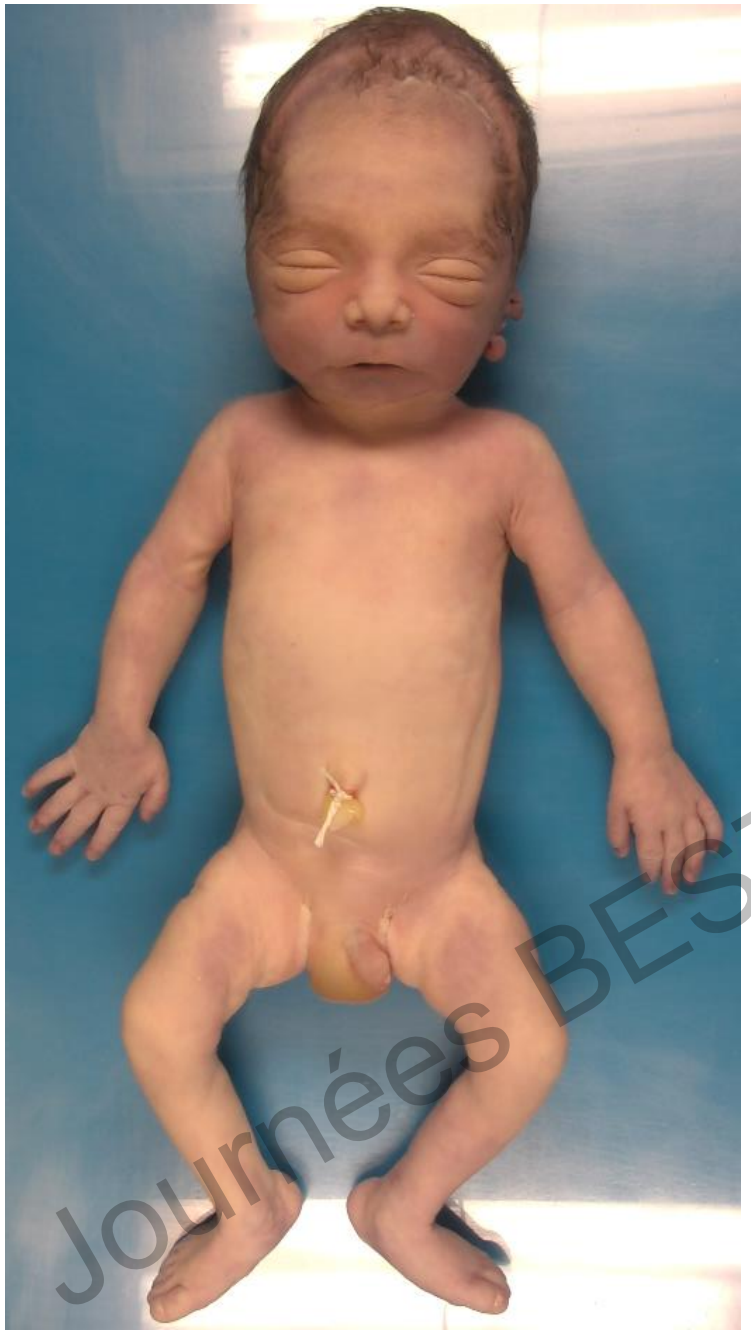

External examination

Growth parameters

	mesure	centile	Term
Weight	1694 g	25e	
CR	27,5 cm	<5e	30
CH	39 cm	<5e	29
Foot	55 mm	<5e	28
HC	30 cm	50e	

Term 33 WG
Male fetus
Normal hands
Valgus feet

Journées BEST OF SOFFOET 15/10/2021

Face

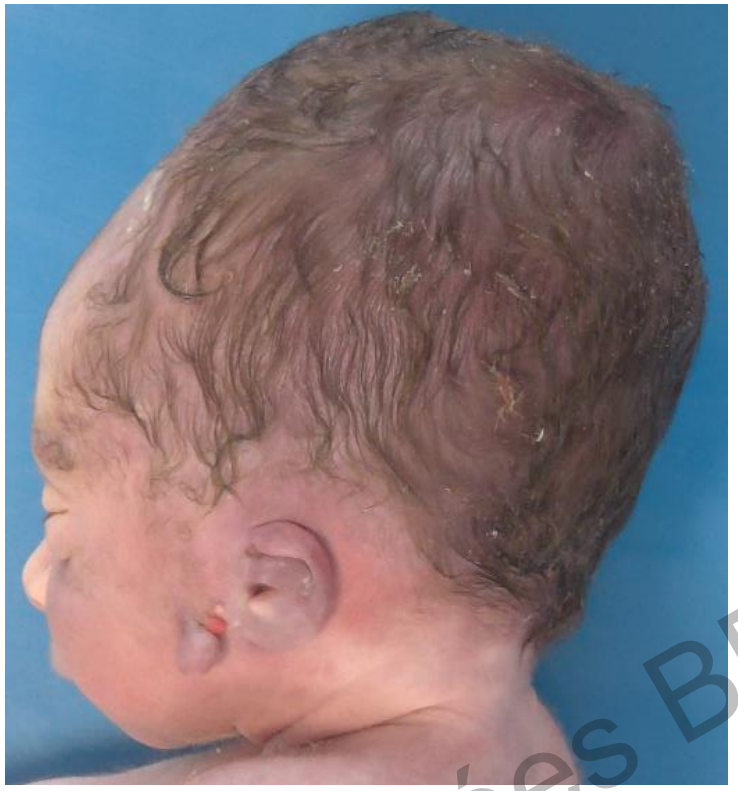

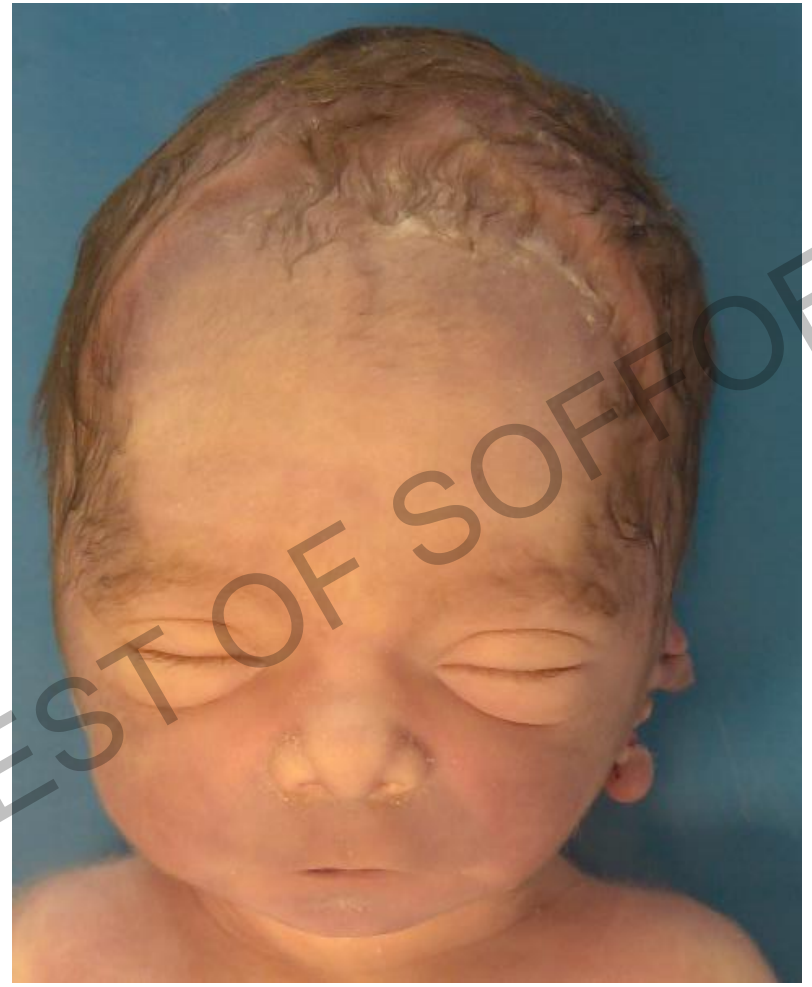

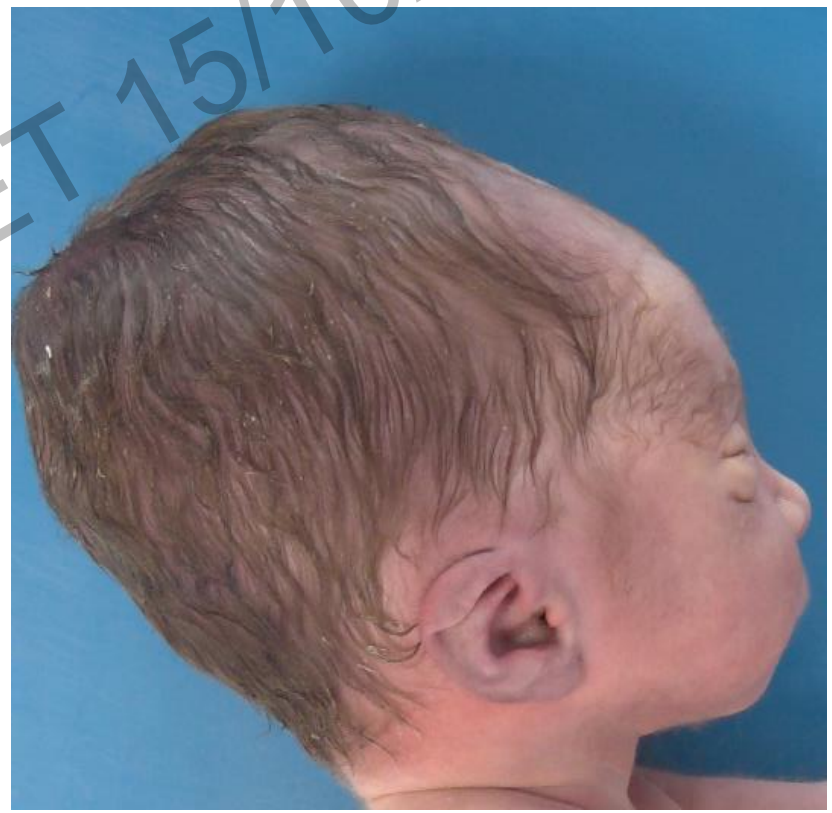

High Forehead, marked infra orbital folds, round nose, thin lips, normal right ear, small chin

Journées BEST OF SOFFOET 15/10/2021

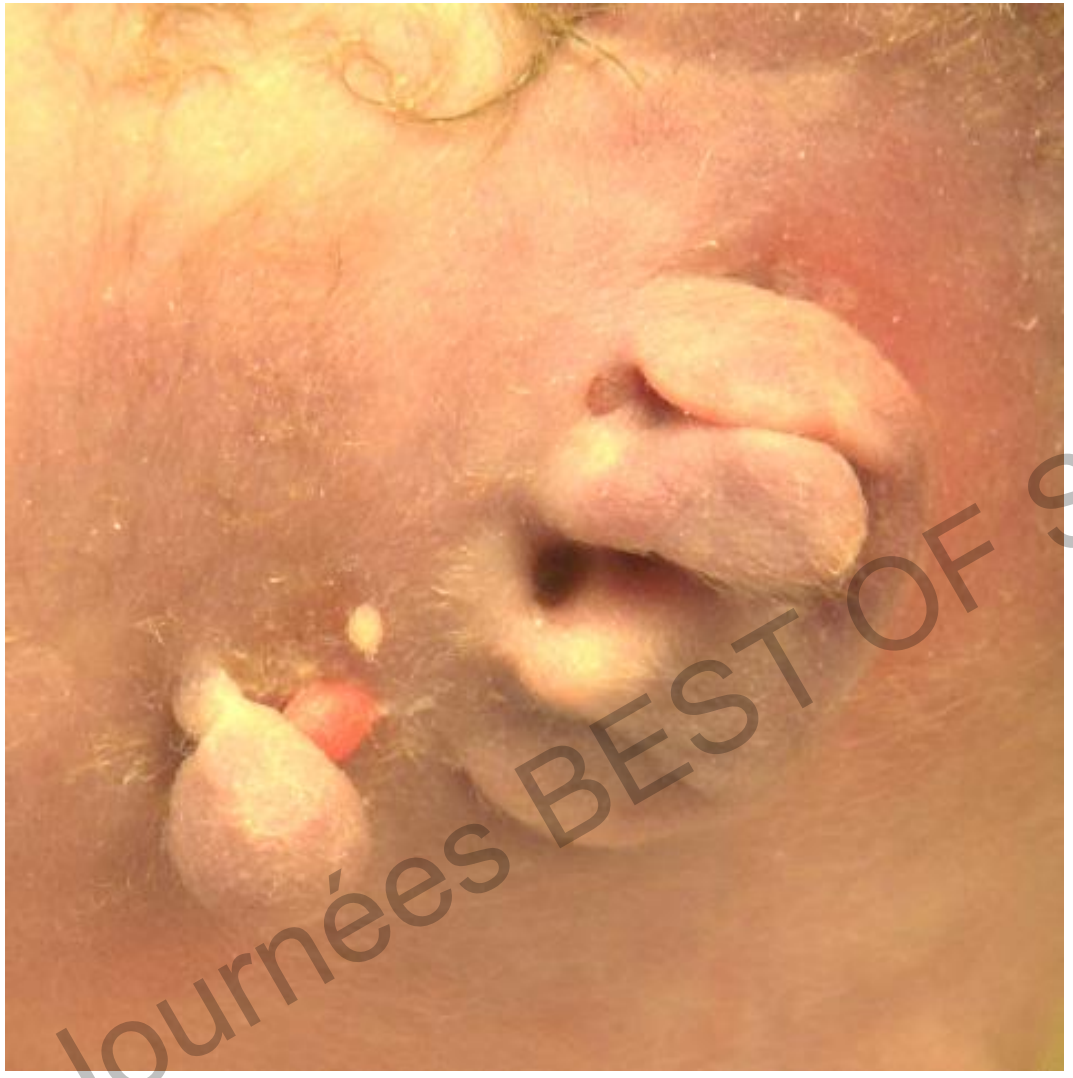

Left ear:
No external auditory canal
3 pre auricular tags, 1 auricular tag

Journées BEST OF SOFFOET 15/10/2021

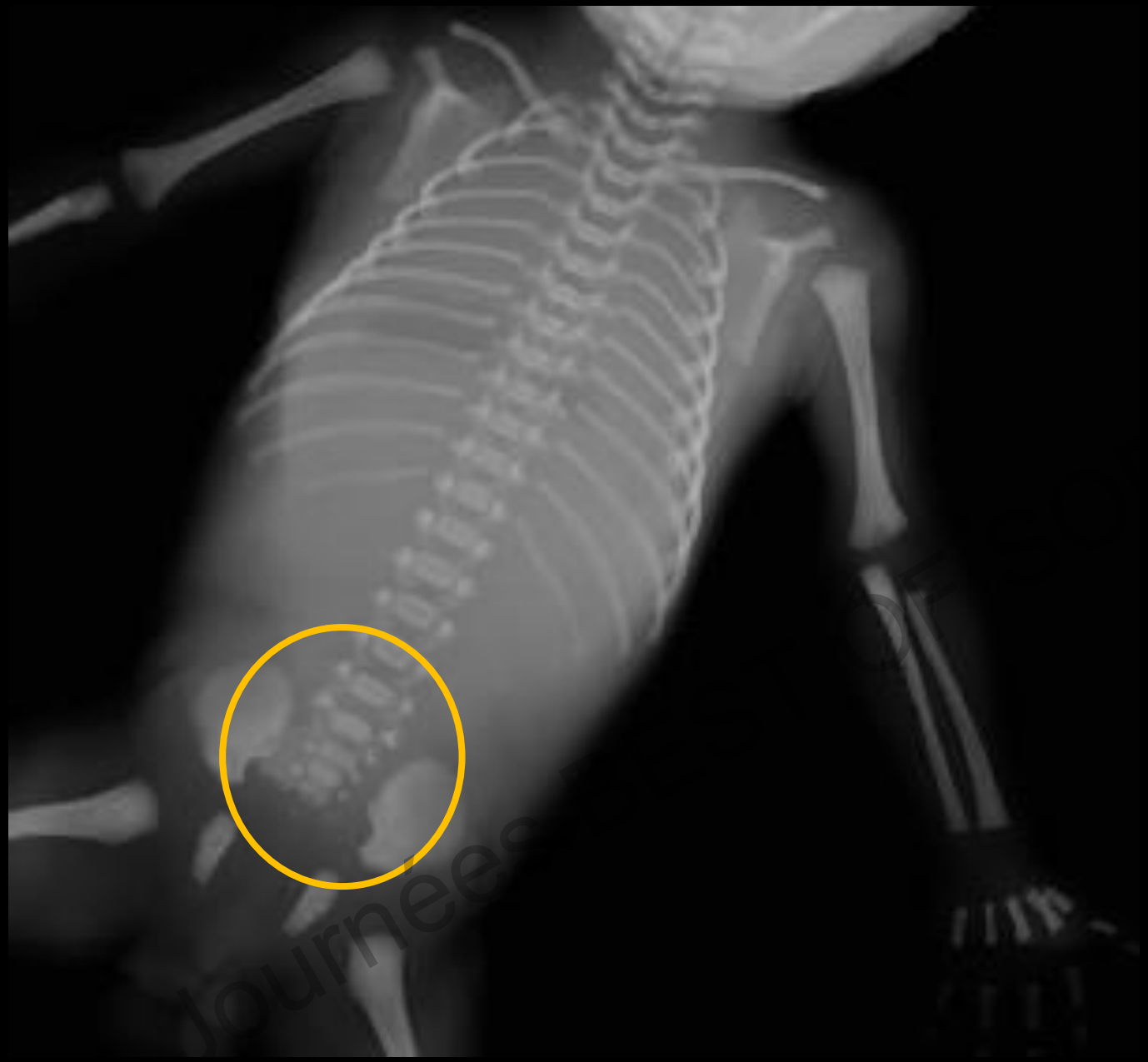

X rays

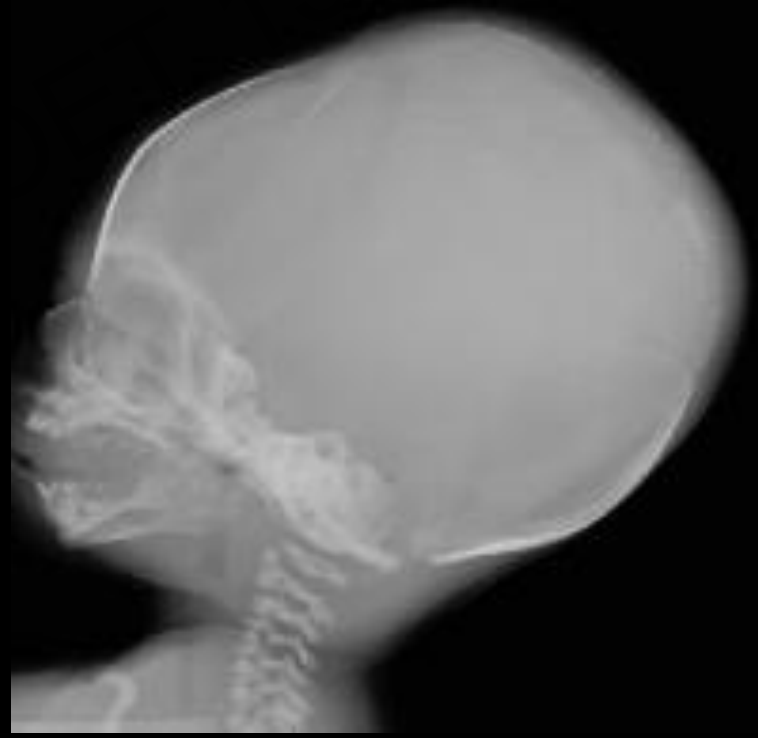

Short long bones, size for 29 WG
Abnormal segmentation of the vertebrae S1

Synthesis

Male fetus, 33 WG, with growth restriction

- Facial dysmorphism with pre auricular and auricular tags nodules on left ear avec ear conduct aplasia
- Short long bones
- Vertebral anomaly

-no other visceral malformation, normal brain examination

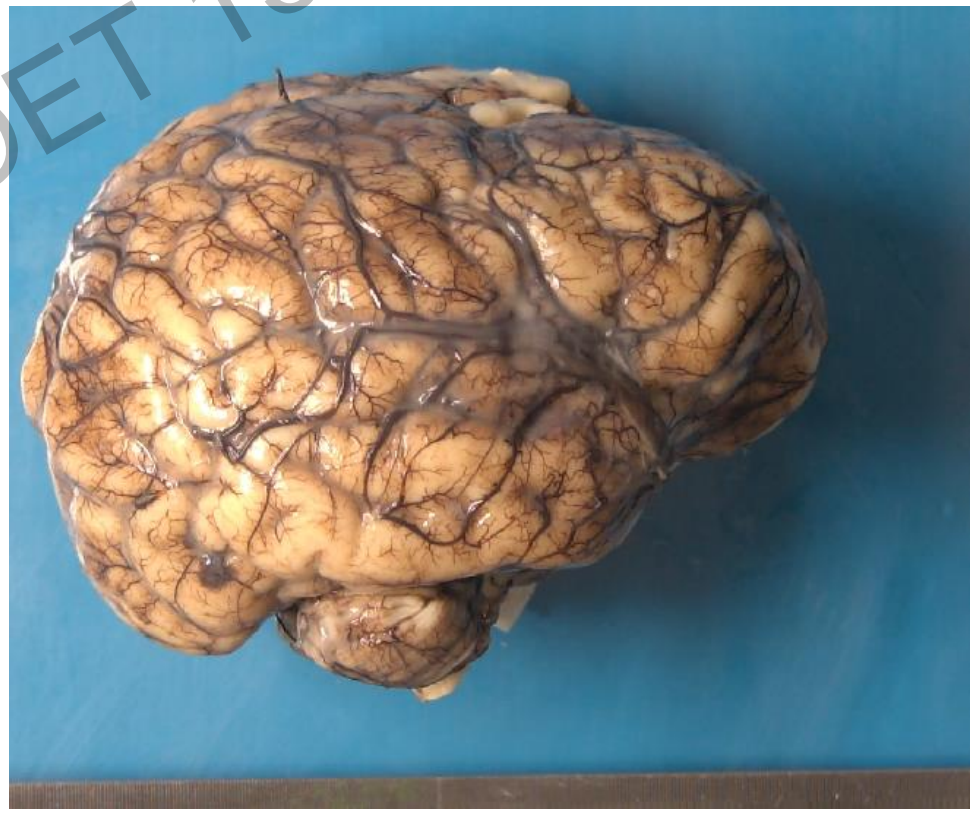

Journées BEST OF SOFFOET 15/10/2021

Verheij syndrome

- Chr 8q24.3 deletion
- Growth retardation, developpement delay, facial dysmorphism, microcephaly, vertebral abnomarlities, ocular coloboma, renal and cardiac defects
- Dauber identified *PUF60* as a cause of Verheij syndrome

Case Reports > Eur J Med Genet. Sep-Oct 2009;52(5):353-7. doi: 10.1016/j.ejmg.2009.05.006. Epub 2009 May 21.

An 8.35 Mb overlapping interstitial deletion of 8q24 in two patients with coloboma, congenital heart defect, limb abnormalities, psychomotor retardation and convulsions

J B G M Verheij [1], S A de Munnik, T Dijkhuizen, N de Leeuw, D Olde Weghuis, G J van den Hoek, R S Rijlaarsdam, Y E M Thomasse, F G Dikkers, C L M Marcelis, C M A van Ravenswaaij-Arts

> Am J Hum Genet. 2013 Nov 7;93(5):798-811. doi: 10.1016/j.ajhg.2013.09.010. Epub 2013 Oct 17.

SCRIB and PUF60 are primary drivers of the multisystemic phenotypes of the 8q24.3 copy-number variant

Andrew Dauber [1], Christelle Golzio, Cécile Guenot, Francine M Jodelka, Maria Kibaek, Susanne Kjaergaard, Bruno Leheup, Danielle Martinet, Malgorzata J M Nowaczyk, Jill A Rosenfeld, Susan Zeesman, Janice Zunich, Jacques S Beckmann, Joel N Hirschhorn, Michelle L Hastings, Sebastien Jacquemont, Nicholas Katsanis

Journées BEST OF SOFEOET 15/10/2021

First prenatal case of Chr 8q24.3 deletion

- Growth retardation,
- Dysmorphology: ear malformation, bitemporal narrowing, anteverted nares, long flat philtrum, thin upper lip, cleft palate, micro retrognathism, short neck,
- Hand anomalies,
- Vertebral anomalies,
- Cardiac defect (AVSD and hypoplastic aortic arch)

Case Reports > Am J Med Genet A. 2016 Jan;170A(1):239-42. doi: 10.1002/ajmg.a.37411. Epub 2015 Oct 5.

First fetal case of the 8q24.3 contiguous genes syndrome

Constance Wells [1], Emmanuel Spaggiari [1 2 3], Valérie Malan [1 3], Julien J Stirnemann [2 3], Tania Attie-Bitach [1 3], Yves Ville [2 3], Michel Vekemans [1 3], Bettina Bessieres [1], Serge Romana [1 3]

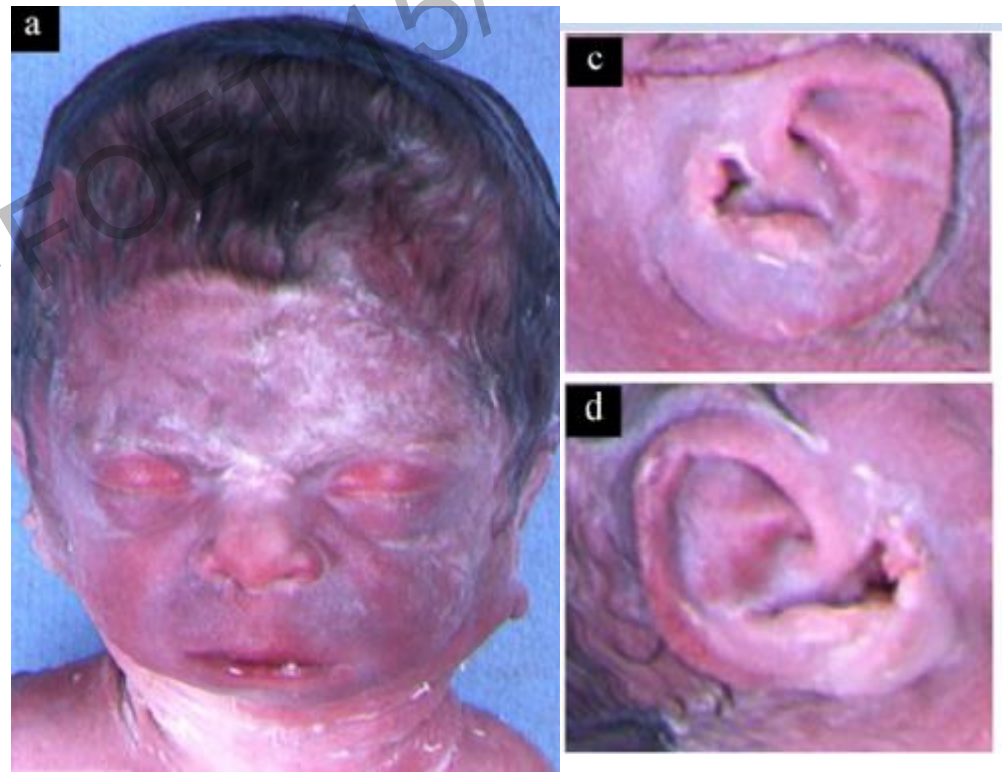

Journées BEST OF SOFFOET 15/10/2021

PUF60

Table 1 – Clinical and Molecular features of individuals with *PUF60* variants

Individual	1(DDD275875)	2(DDD273705)	3(DDD271317)	4(DDD272812)	5(DDD270021)	6(DDD263362)	7	8(3781-3781)	9	10	11	12	Fraction of cases with feature
Mutation (hg19, chr8)	g.144899838_144899839insTTTT	g.144900247T>C	g.144900425C>T	g.144898898C>T	g.144898783_144898793del	g.144900578C>T	g.144899761C>T	g.144900247T>G	g.144899550dup	g.144898991T>C	g.144900212_144900230del	g.144911449C>T	
Effect	Frameshift	Splice acceptor	Missense	Missense	Frameshift	Missense	Splice donor	Splice acceptor	Frameshift	Splice acceptor	Frameshift	Splice donor	
Protein(ENSP00000434359.1)	p.Thr311Lysfs*137		p.(Glu181Lys)	p.(Gly491Glu)	p.(His526Profs*16)	p.(Asp159Asn)			p.(Thr366Hisfs*81)		p.(Asn207Profs*3)		
cDNA (NM_078480.2)	c.931_932insAAAA	c.604-2A>G	c.541G>A	c.1472G>A	c.1577_1587del	c.475G>A	c.1008+1G>A	c.604-2A>C	c.1094dupG	c.1381-2A>G	c.619_637del	c.24+1G>A	
CADD Score (PHRED)			33	31		17.05						21.4	
Inheritance	*De novo*	*De novo*	*De novo*	*De novo*	*De novo*	*De novo*	*De novo*	*De novo*	*De novo*	*De novo*	*De novo*	*De novo*	
Age (years)	9	3	12	5	7	7	16	2	10	8	4	2	
Sex	Male	Female	Male	Female	Female	Female	Female	Female	Female	Male	Female	Male	8F/4M
Prenatal Growth													
Gestation(weeks)	38	36	39	40	40	36	40	38	40	38	41	40	
Birthweight (g) [z score]	3185[0.016]	2600[0.023]	2560[-1.84]	3820[0.929]	3200[-0.51]	1745[-2.14]	4003[1.33]	2182[-2.11]	3090[-0.78]	2800[-0.84]	2330 [-2.18]	4225 [0.0]	
Birth OFC(cm) [z score]	34[0.08]	34[1.229]	34.2[-0.18]	-	-	29[-2.72]	34[-0.13]	-	-	33[-0.71]		-	

Eur J Hum Genet. 2017 May;25(5):552-559. doi: 10.1038/ejhg.2017.27. Epub 2017 Mar 22.

PUF60 variants cause a syndrome of ID, short stature, microcephaly, coloboma, craniofacial, cardiac, renal and spinal features

Karen J Low [1 2], Morad Ansari [3], Rami Abou Jamra [4], Angus Clarke [5], Salima El Chehadeh [6], David R FitzPatrick [3], Mark Greenslade [7], Alex Henderson [8], Jane Hurst [9], Kory Keller [10], Paul Kuentz [11], Trine Prescott [12], Franziska Roessler [4], Kaja K Selmer [12], Michael C Schneider [13], Fiona Stewart [14], Katrina Tatton-Brown [15], Julien Thevenon [11], Magnus D Vigeland [12], Julie Vogt [16], Marjolaine Willems [17], Jonathan Zonana [10], D D D Study [18], Sarah F Smithson [1 2]

Journées BEST OF SOFFOET 15/10/2021

Postnatal growth													
Weight (centile) [z score]	5.6[-1.59]	3[-1.95]	44[-0.14]	28.9 [-0.56]	55[0.144]	68[0.47]	0[-4.47]	0[-3.52]	22.2[-0.76]	0 [-3.06]	56.6 [0.165]	72.3 [0.59]	
Height (centile) [z score]	3.5 [1.81]	1[-3.05]	1.1[-2.3]	11.1[-1.22]	5[-1.63]	3[-1.88]	0.2[-2.85]	0.4[-2.69]	1.2[-2.26]	18 [-0.92]	48.6 [-0.04]	65 [0.38]	5/12 Z score<-2SD
OFC:(centile) [z score]	0.7[-2.48]	26[-0.64]	8.5[-1.37]	24.9 [-0.68]	10[-1.27]	0[-4.22]	1.9[-2.09]	3.1[-1.86]	13.5[-1.1]	0.1[-2.99]	3 [-2.53]	99 [2.75]	5/12 Z score<-2SD
Renal	-	-	right renal agenesis	-	-	-	-	-	-	-	horseshoe kidney,	-	2/12
Coloboma	-	-	right disc	-	right iris	-	-	-	-	-	-	-	2/12
Ocular	-	esotropia, hypermetropia	bilateral dysplastic discs	-	-	borderline optic nerve hypoplasia, hypermetropia, mild left ptosis	myopia	-	amblyopia	strabismus	-	-	6/12
Cardiac	-	perimembranous vsd, pfo, pda	AVSD	-	-	-	tetralogy of fallot	VSD,Coarctation	-	-	truncus arteriosus	-	5/12

Journées BEST OF SOFFOET 15/10/2021

Skeletal	scoliosis	-	complex congenital C spine abnormality	-	-	pectus excavatum	hemivertebrae, pectus excavatum, spina bifida	-	spinal dysraphism	pectus excavatum	-	pectus excavatum	7/12
Hand anomalies	-	-	-	-	+	+	+/polydactyly	-	+	+	-	-	5/12
Joint laxity/dislocation	+	+	-	-	-	-	+	-	+/hip	+	-	+	6/12
Oral	+	-	+	-	+	-	+	-	+	+	+	-	7/12
Feeding	+	-	-	-	+	-	+	+	+	+	+	-	7/12
Intellectual Disability	+	+	+	+	+	+	+	+	+	+	+	+	12/12
Auditory	-	+	+	-	-	+	+	-	+	+	-	-	6/12
Hypertrichosis	-	-	-	+	-	+	+	+	+	-	-	-	5/12
Other	Hypospadias, HBH bodies	Left sided superficial neck mass	Bell's palsy, right inguinal hernia	Superior oblique oculomotor syndrome, Stereotypies, Constipation	Depigmented streak of hair, Pancreatic exocrine insufficiency	Periventricular leukomalacia, Thin corpus callosum, cyst at cerebellopontine angle		CdLS-like phenotype		Micrognathia,skin extensibility	Submucous cleft palate	Cerebral ventriculomegaly, partial agenesis corpus callosum, periventricular loss of white matter	

Journées BEST OF SOFFOET 15/10/2021

Ears malformation in *PUF60* mutated case

- asymetric and posteriorly rotated ears
- Detached ears with cup shape
- Triangular ears with flattened helices
- Preauricular pits/ tags
- Branchial cleft cysts and branchial fistula

- -> first case with anotia

Journées BEST OF SOFFOET 15/10/2021

Spliceosomopathies

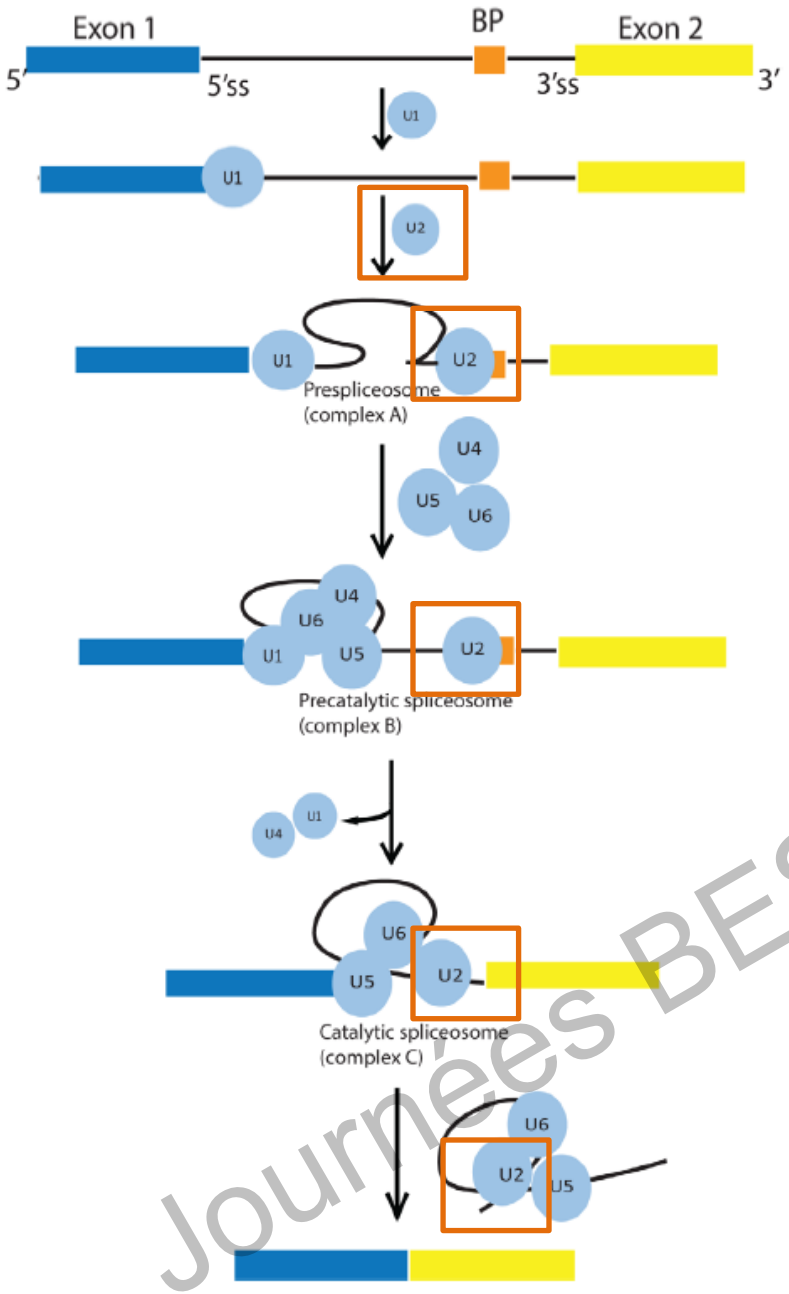

FIGURE 2 Schematic representation of the splicing reaction

spliceosome is a complex of RNA and proteins that function together to identify intron-exon junctions

splice out the introns, and join the flanking exons

Review > Dev Dyn. 2020 Aug;249(8):924-945. doi: 10.1002/dvdy.183. Epub 2020 May 21.

Spliceosomopathies and neurocristopathies: Two sides of the same coin?

Marie-Claude Beauchamp [1 2], Sabrina Shameen Alam [2 3], Shruti Kumar [2 3], Loydie Anne Jerome-Majewska [1 2 3 4]

Journées BEST OF SOFFOET 15/10/2021

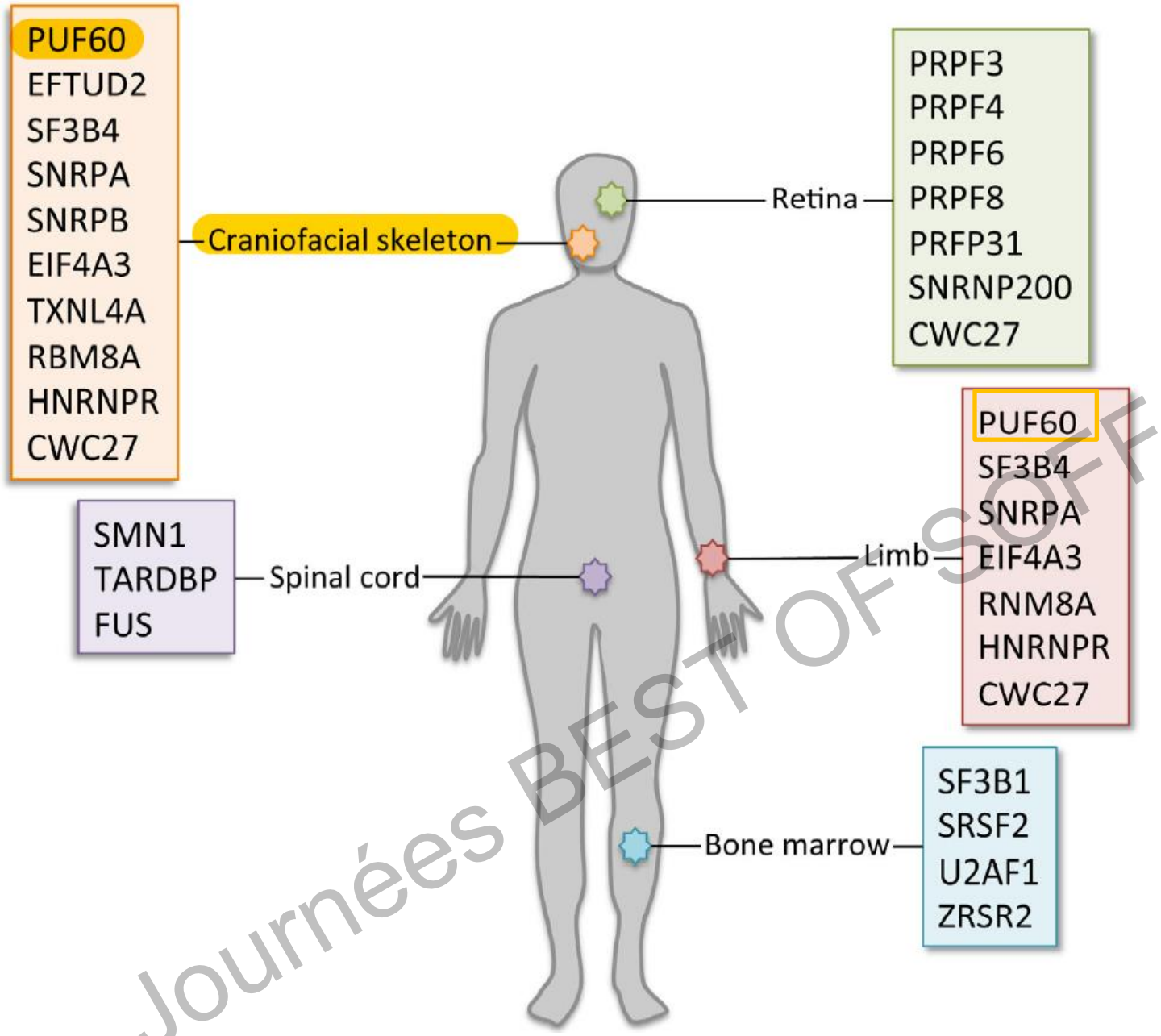

EFTUD2 Guion Almeida
SF3B4 Nager
SNRHP cerebro costo mandibular

Review > Dev Dyn. 2020 Sep;249(9):1038-1046. doi: 10.1002/dvdy.214. Epub 2020 Jun 29.

Spliceosomopathies: Diseases and mechanisms

Casey Griffin [1], Jean-Pierre Saint-Jeannet [1]

Affiliations + expand

PMID: 32506634 DOI: 10.1002/dvdy.214

Journées BEST OF SOFFOET 15/10/2021

- Guion Almeida
- *EFTUD2*

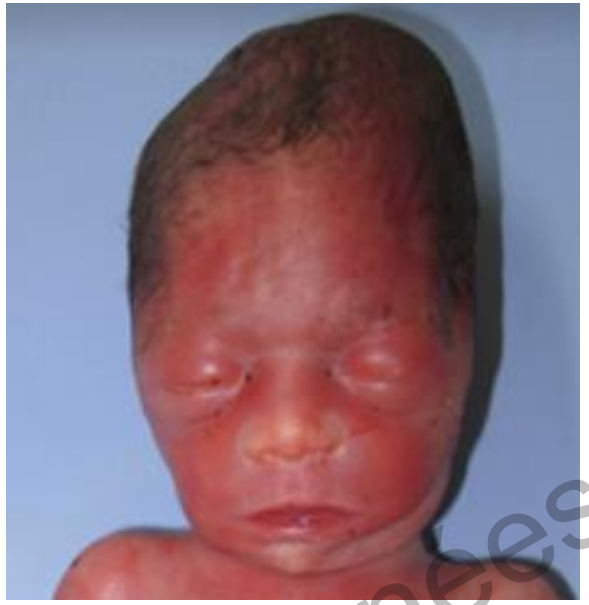

Bron,
Dr Sablaville/ Dr Vasiljevic,
2011

- Nager
- *SF3B4*

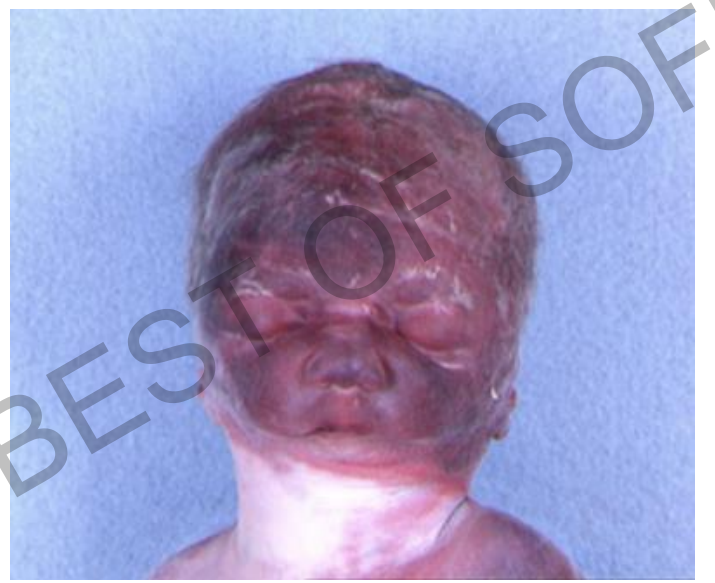

Hopital Necker, Paris,
Dr Bessières
2013

- Cerebro Costo Mandibular
- *SNRHP*

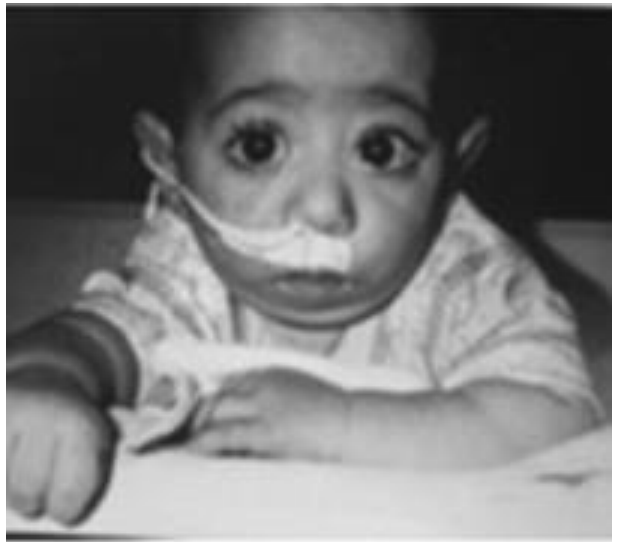

Hum Mutat. 2015 Feb;36(2):187-90. doi: 10.1002/humu.22729. Epub 2014 Dec 11.

Mutations in SNRPB, encoding components of the core splicing machinery, cause cerebro-costo-mandibular syndrome

Séverine Bacrot [1], Mathilde Doyard, Céline Huber, Olivier Alibeu, Niklas Feldhahn, Daphné Lehalle, Didier Lacombe, Sandrine Marlin, Patrick Nitschke, Florence Petit, Marie-Paule Vazquez, Arnold Munnich, Valérie Cormier-Daire

Journées BEST OF SOFFOET 15/10/2021

- Verheij JBGM, de Munnik SA, Dijkhuizen T, de Leeuw N, Olde Weghuis D, van den Hoek GJ, et al. An 8.35 Mb overlapping interstitial deletion of 8q24 in two patients with coloboma, congenital heart defect, limb abnormalities, psychomotor retardation and convulsions. Eur J Med Genet. oct 2009;52(5):353-7.
- El Chehadeh S, Kerstjens-Frederikse WS, Thevenon J, Kuentz P, Bruel A-L, Thauvin-Robinet C, et al. Dominant variants in the splicing factor PUF60 cause a recognizable syndrome with intellectual disability, heart defects and short stature. Eur J Hum Genet. janv 2017;25(1):43-51.
- Dauber A, Golzio C, Guenot C, Jodelka FM, Kibaek M, Kjaergaard S, et al. SCRIB and PUF60 Are Primary Drivers of the Multisystemic Phenotypes of the 8q24.3 Copy-Number Variant. Am J Hum Genet. 7 nov 2013;93(5):798.
- Low KJ, Ansari M, Abou Jamra R, Clarke A, El Chehadeh S, FitzPatrick DR, et al. PUF60 variants cause a syndrome of ID, short stature, microcephaly, coloboma, craniofacial, cardiac, renal and spinal features. Eur J Hum Genet. mai 2017;25(5):552-9.
- Santos-Simarro F, Vallespin E, del Pozo A, Ibañez K, Silla JC, Fernandez L, et al. Eye coloboma and complex cardiac malformations belong to the clinical spectrum of *PUF60* variants. Clin Genet. sept 2017;92(3):350-1.
- First fetal case of the 8q24.3 contiguous genes syndrome - Wells C, Spaggiari E, Malan V, Stirnemann JJ, Attie-Bitach T, Ville Y, Vekemans M, Bessieres B, Romana S. 2016. Am J Med Genet Part A 170A:239–242. doi/10.1002/ajmg.a.37411
- Strande NT, Riggs ER, Buchanan AH, Ceyhan-Birsoy O, DiStefano M, Dwight SS, et al. Evaluating the Clinical Validity of Gene-Disease Associations: An Evidence-Based Framework Developed by the Clinical Genome Resource. Am J Hum Genet. 1 juin 2017;100(6):895-906.
- Beauchamp M, Alam SS, Kumar S, Jerome-Majewska LA. Spliceosomopathies and neurocristopathies: Two sides of the same coin? Dev Dyn. août 2020;249(8):924-45.
- C G, Jp S-J. Spliceosomopathies: Diseases and mechanisms. Dev Dyn Off Publ Am Assoc Anat [Internet]. sept 2020 [cité 7 oct 2021];249(9). Disponible sur: https://pubmed.ncbi.nlm.nih.gov/32506634/
- Hastings ML, Allemand E, Duelli DM, Myers MP, Krainer AR. Control of pre-mRNA splicing by the general splicing factors PUF60 and U2AF(65). PloS One. 20 juin 2007;2(6):e538.
- C G, E G, G S, F I, A W, M B, et al. A de novo PUF60 mutation in a child with a syndromic form of coloboma and persistent fetal vasculature. Ophthalmic Genet [Internet]. déc 2017 [cité 6 oct 2021];38(6). Disponible sur: https://pubmed.ncbi.nlm.nih.gov/28471317/

Journées BEST OF SOFFOET 15/10/2021

SoFFœt
Société Française de Fœtopathologie

ASSISTANCE PUBLIQUE HÔPITAUX DE PARIS
Necker ENFANTS MALADES
HÔPITAL UNIVERSITAIRE

Thank you

- **Fœtopathologie:**
  - **B. Bessières**
  - **L. Lœuillet**
  - **G. Petrilli**
  - **N. Roux**
  - **H. Salhi**
  - **E. Spaggiari**

- **Echographistes du CPDPN:**
  - **Necker – Enfants Malades**

- **Génétique:**
  - **T. Attié-Bitach**

Journées BEST OF SOFFOET 15/10/2021