Fetal series of ventriculomegaly and aqueductal stenosis: causes and input of Next Generation Sequencing

Romain NICOLLE
resident in genetics
15/10/2021

SoFFœt
Société Française de Fœtopathologie

Necker
ENFANTS MALADES
HÔPITAL UNIVERSITAIRE

Introduction

- 2% of newborns: at least one congenital malformation
- 10-20% of fetuses with at least one congenital malformation: cerebral abnormality
- Cerebral malformations can affect every anatomical structure, can be isolated or associated with other malformations (cerebral or extra-cerebral)

- Ventricular dilatation = ventriculomegaly
- Definition: ventricular width > 10 mm
  - mild: 10-12 mm
  - moderate: 12-15 mm
  - severe > 15 mm
- 1-3/1000 newborns
- Can be detected/monitored during pregnancy by US

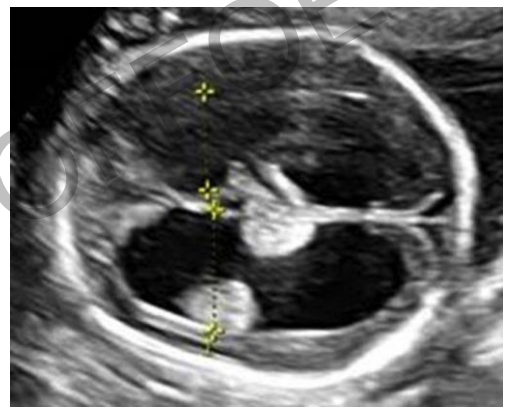

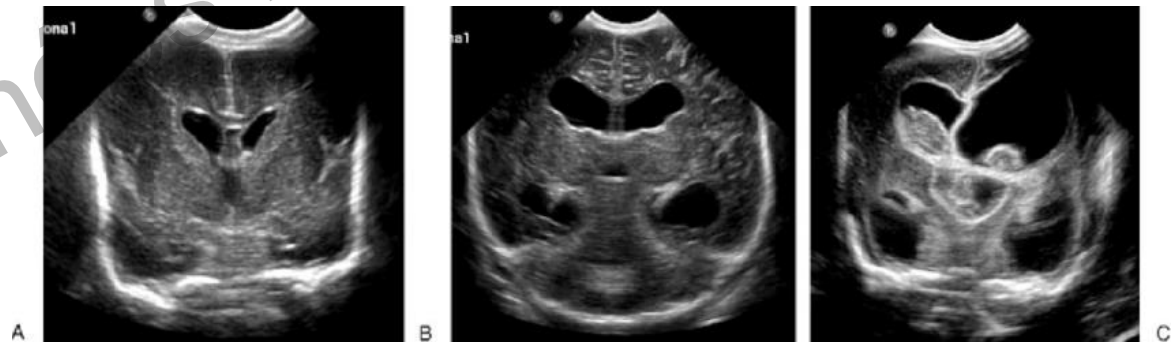

Ventriculomegaly

Obstructive

Non-obstructive:
overproduction of cerebrospinal fluid

Cerebral atrophy:
ventriculomegaly *ex vacuo*

Acquired:
- Congenital Infection
- Intra-cerebral hemorrage
- External compression

Malformative:
- Clinical entities/syndromes with several malformations: Chiari, Dandy-Walker, holoprosencephaly, diencephalosynapsis, rhombencephalosynapsis
- Aqueductal stenosis or atresia

Known causes: del6qter, *L1CAM, MPDZ, CRB2, SMARCC1, PDHA1* etc.

Fetal cohort

- Review from 1992 to 2021: termination of pregnancy (TOP) for prenatal ventriculomegaly with aqueductal stenosis

- 54 fetuses from 48 families: foetopathological examination
  - Additional clinical features
  - Histopathological examination

- Genetic testing:
  - Standard karyotyping 22
  - CMA 39
  - Sanger sequencing 15
  - Panel sequencing 9
  - Exome sequencing 7
  - Genome sequencing 8

Next-Generation Sequencing

Results

- Genetic causes:
  - Del6q27 2 fetuses from 2 families
  - *PDHA1* 2 fetuses from 2 families
  - *L1CAM* 2 fetuses from 2 families
  - *CRB2* 3 fetuses from 2 families
  - *LIG4* 4 fetuses from 2 families
  - *TIMMDC1* 2 fetuses from 1 family
  - Methylation abnormality: 1 fetus with UPD (Uniparental Isodisomy) for all the chromosomes in a mosaic state

- In total we established a diagnosis in 12/48 families (~25%): 16/54 fetuses
- NGS (panel/exome/genome sequencing): increase in diagnosis rate

Results

- Genetic causes:
  - Del6q27 2 fetuses from 2 families
  - *PDHA1* 2 fetuses from 2 families
  - *L1CAM* 2 fetuses from 2 families
  - *CRB2* 3 fetuses from 2 families
  - *LIG4* 4 fetuses from 2 families
  - *TIMMDC1* 2 fetuses from 1 family
  - Methylation abnormality: 1 fetus with UPD (Uniparental Isodisomy) for all the chromosomes in a mosaic state

- In total we established a diagnosis in 12/48 families (~25%): 16/54 fetuses
- NGS (panel/exome/genome sequencing): increase in diagnosis rate

Illustration: *CRB2*

Family 1

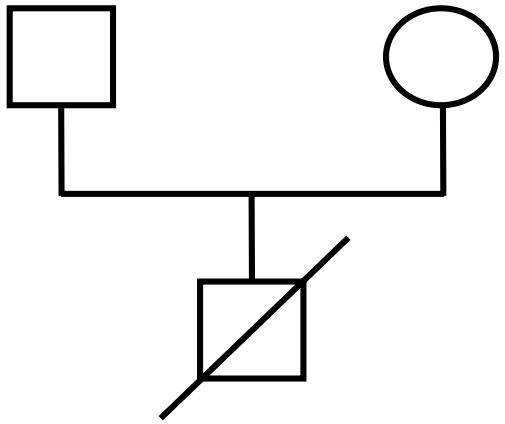

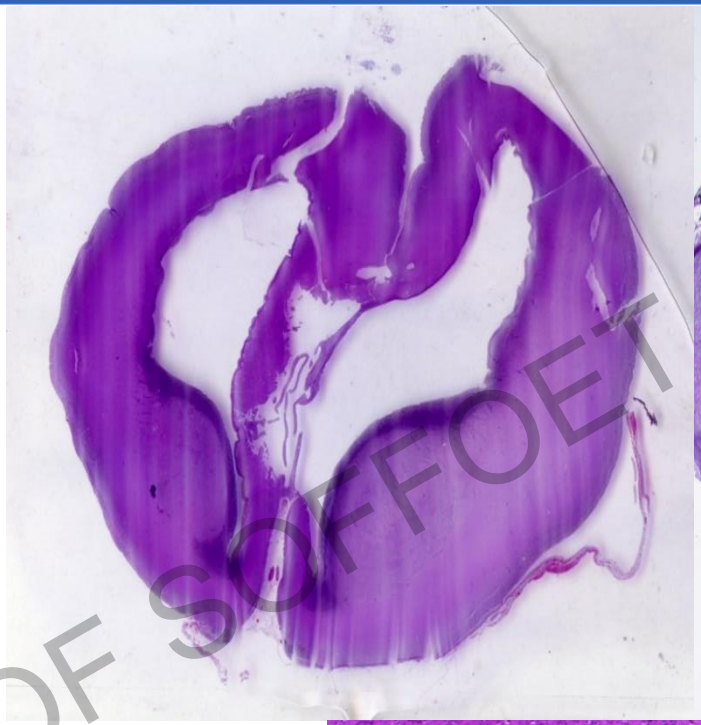

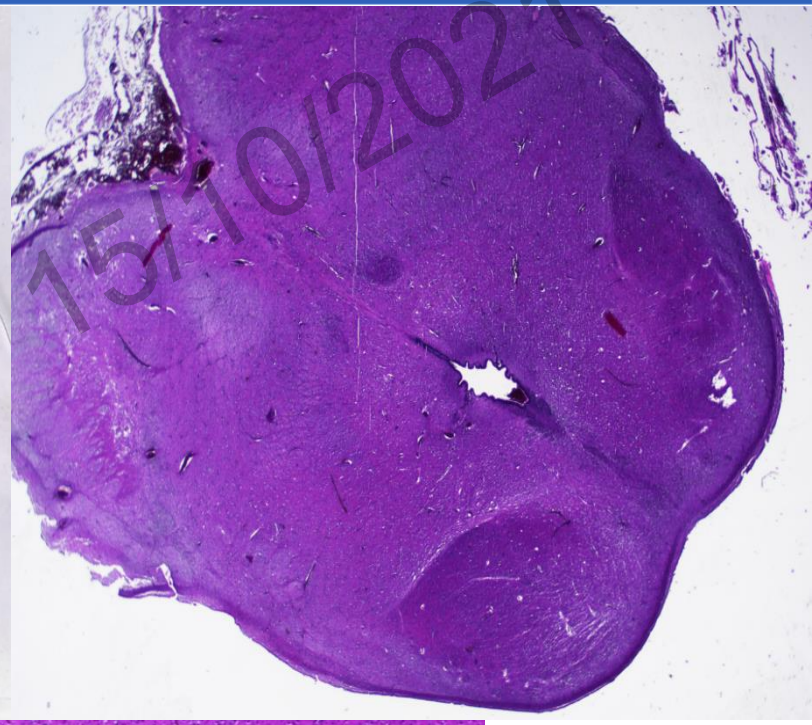

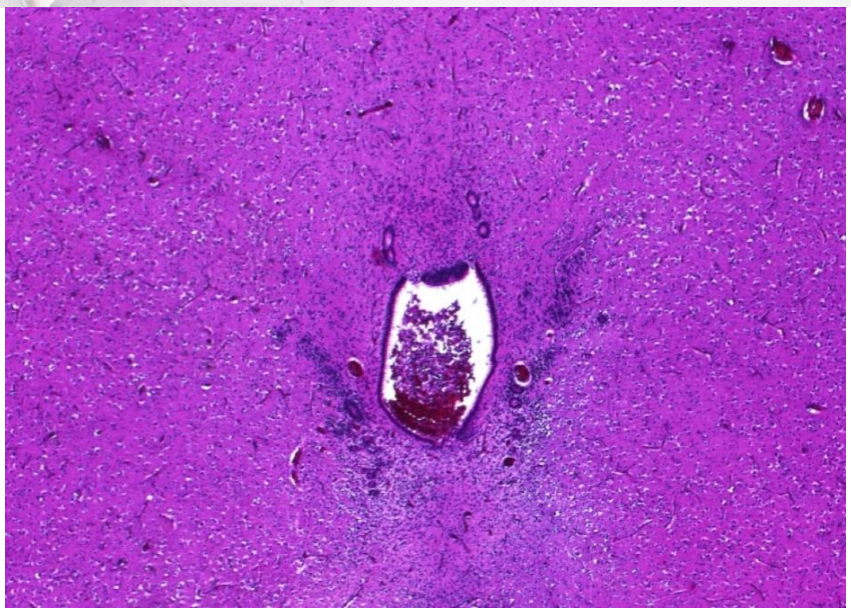

- NM_173689.6:c.2325C>A, p.(Cys755*)
- NM_173689.6:c.2400C>G, p.(Asn800Lys)

Illustration: *CRB2*

Family 2

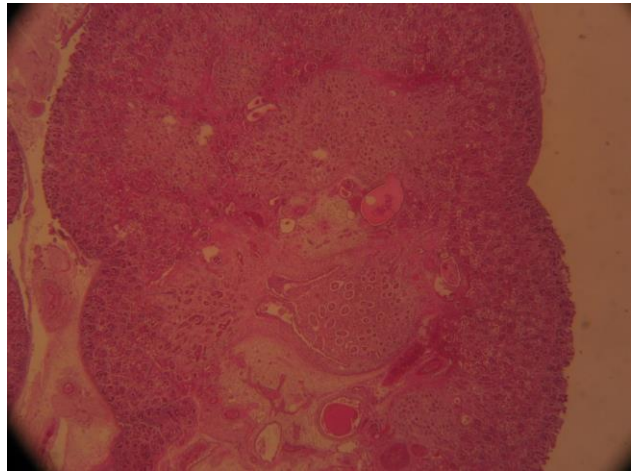

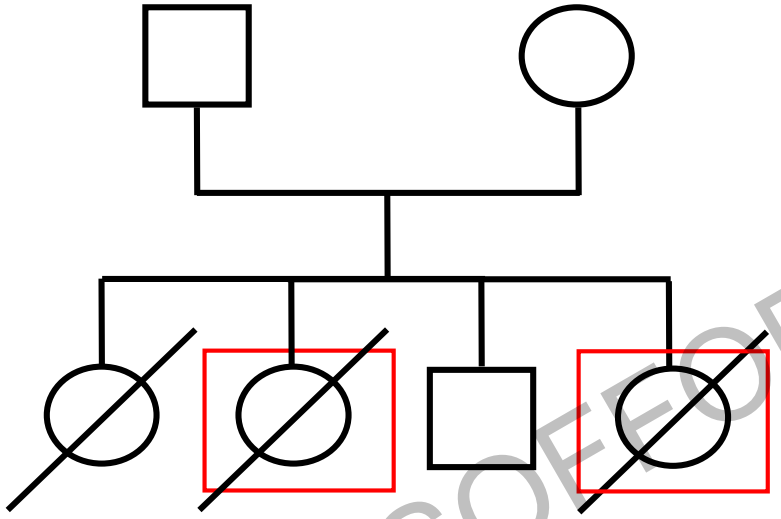

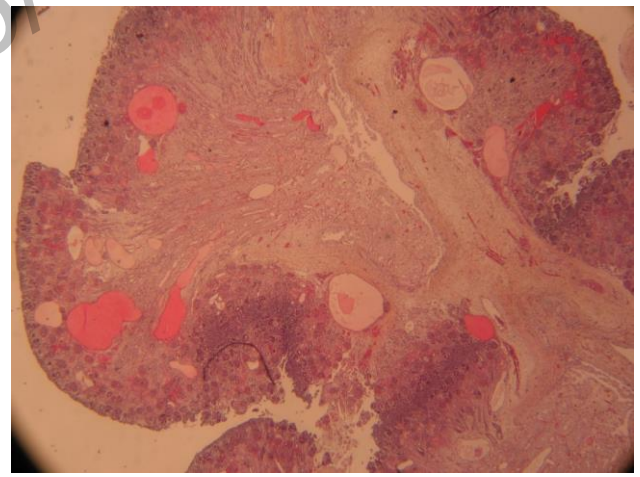

- NM_173689.6:c.2400C>G, p.(Asn800Lys)
- NM_173689.6:c.3089_3104dup, p.(Gly1036Alafs*43)

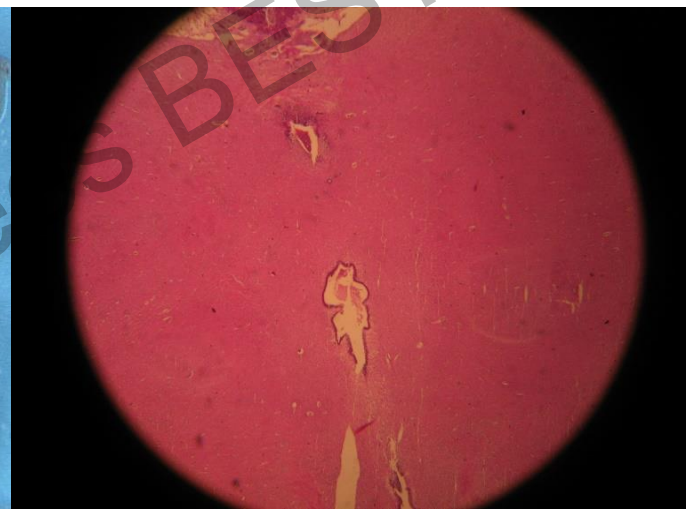

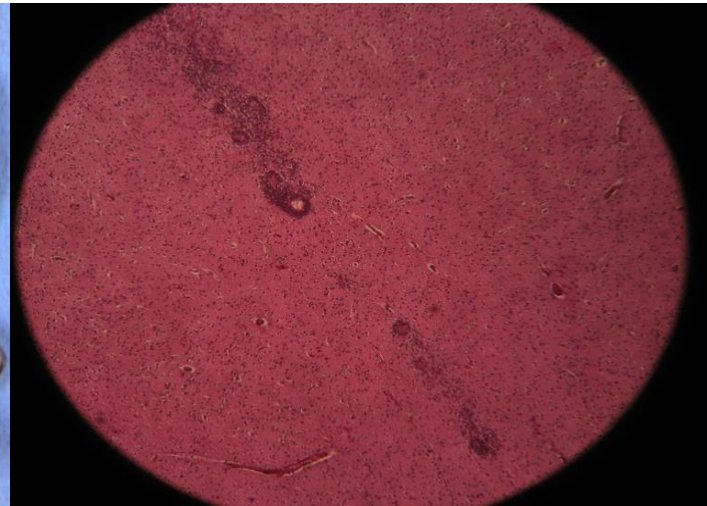

- *CRB2* (Crumbs Cell Polarity Complex Component 2) (OMIM 609720)
  - 9q33.3, 13 exons
  - Involved in cell polarity (same metabolic pathway as *MPDZ*)
  - Focal segmental glomerulosclerosis (OMIM 616220, AR) in 2015 (Ebarasi et al. PMID 25557779)
  - Ventriculomegaly with cystic kidney disease (OMIM 219730, AR) in 2015 (Slavotinek et al. PMID 25557780)
    - Cystic tubular dilatation in the corticomedullary area and medulla
    - Cysts contain eosinophilic proteinaceous material
    - Ventriculomegaly
    - Focal hyperplasia of the choroid plexus
    - Seizures
    - Gray matter heterotopia in some patients
    - polyhydramnios

Illustration: *LIG4*

Family 3

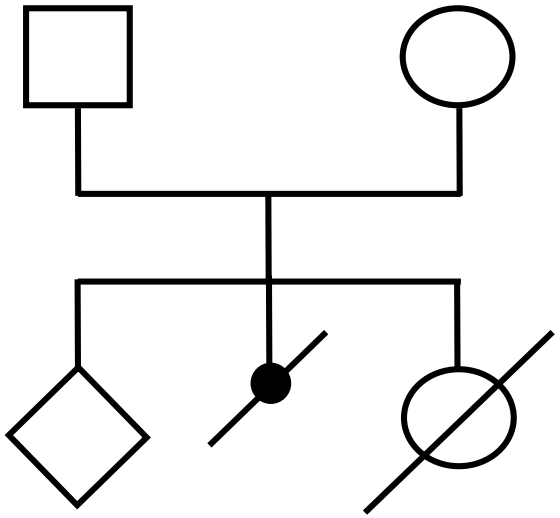

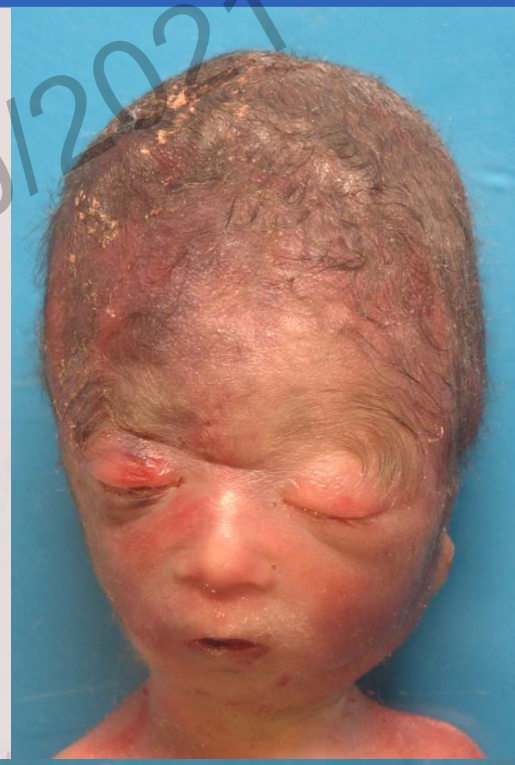

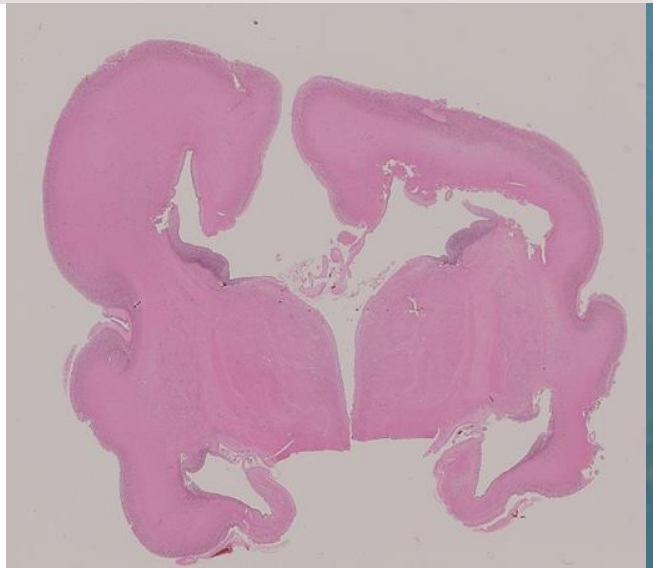

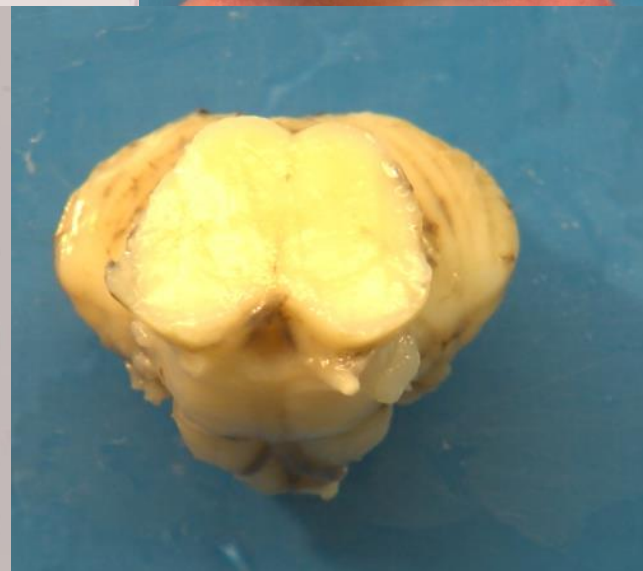

- Mild dysmorphic features
- Heart: atrial septum defect
- clinodactyly of the 5th finger

- NM_002312.3:c.907G>C, p.(Gly303Arg)
- NM_002312.3:c.1512_1513del, p.(Arg505Cysfs*12)

Illustration: *LIG4*

Family 4

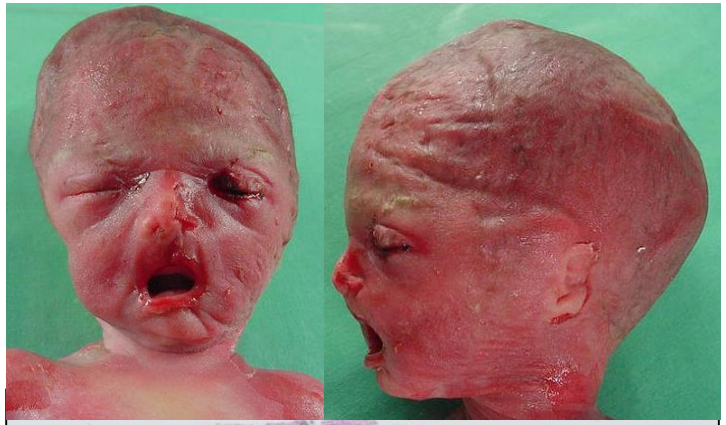

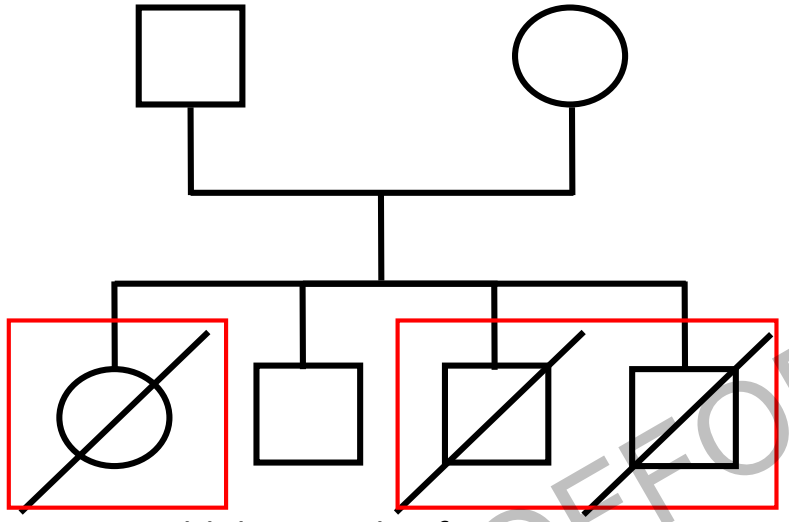

- Mild dysmorphic features
- Heart: atrioventricular defect
- clinodactyly of the 5th finger

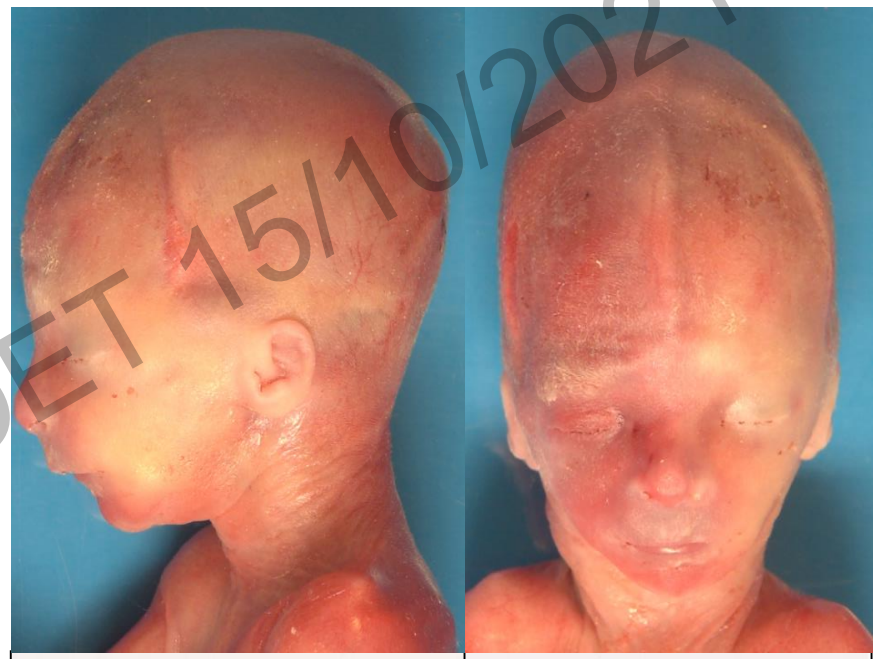

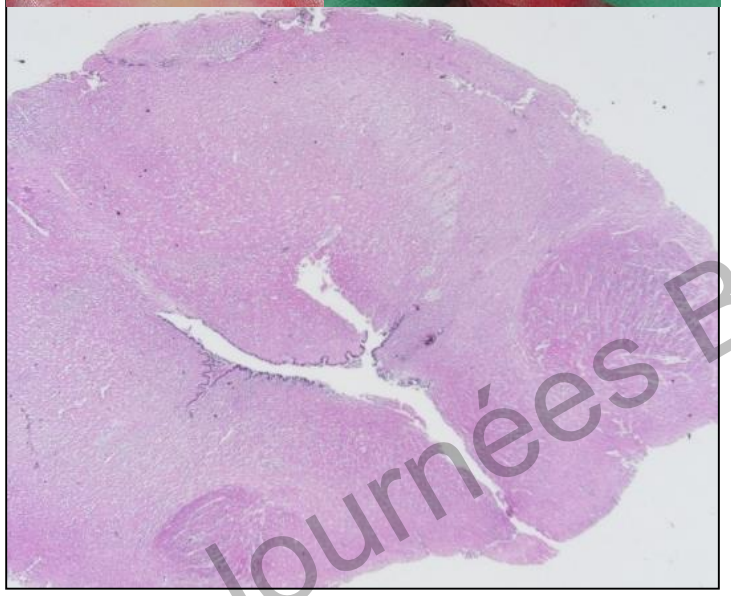

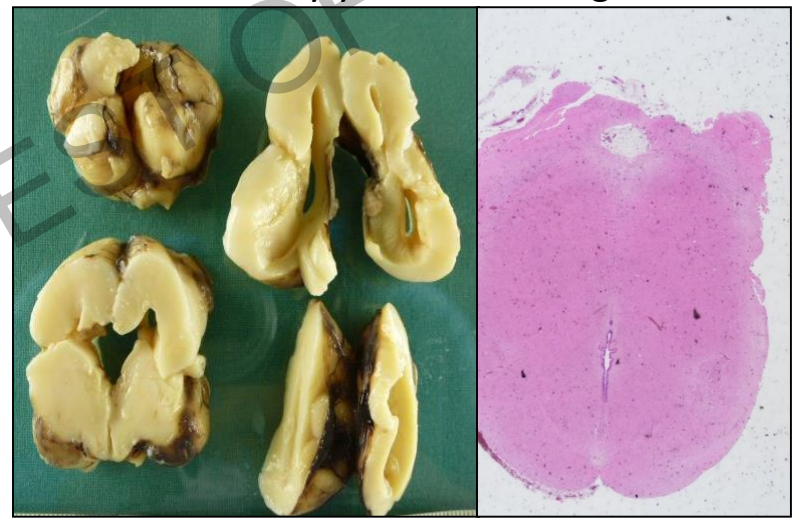

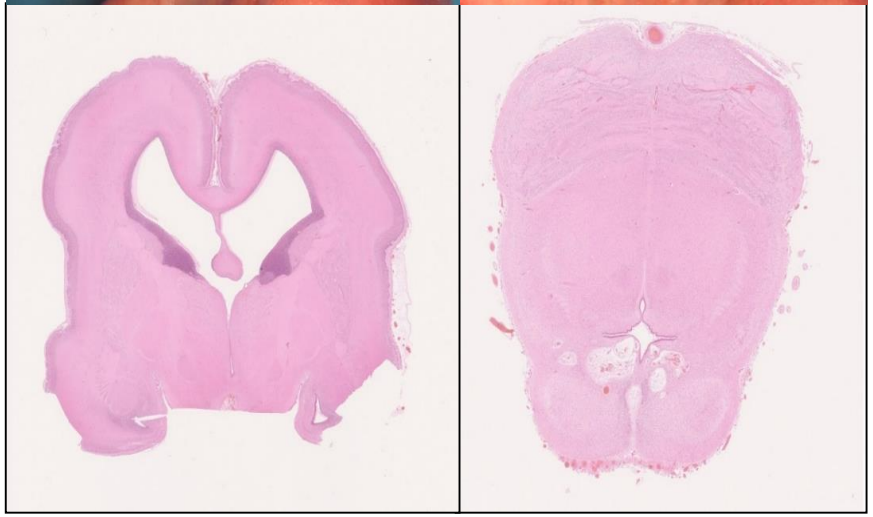

- NM_002312.3:c.2440C>T, p.(Arg814*)
- NM_002312.3:c.1512_1513del, p.(Arg505Cysfs*12)

- *LIG4* (Ligase IV, DNA, ATP-dependent) (OMIM 601837)
  - 13q13.3, 2 exons (only 1 coding exon)
  - Involved in Double-Strand-Breaks DNA-repair: V(D)J recombination and NHEJ
  - LIG4 syndrome (OMIM 606593, AR):
    - IUGR
    - Dysmorphic features: « bird-like » or « Seckel-syndrome like », narrow forehead, hypotelorism, prominent nose, micrognathia
    - Progressive microcephaly
    - Developmental delay
    - Genital anomalies: Micropenis and cryptorchidism, amenorrhea (female)
    - Skin lesions: photosensibility and psoriasis
    - Hematology: Pancytopenia, thrombocytopenia, myelodysplasia

  - Involved in embryonic neuronal development: neural stem and progenitor cell population survival (Frank et al. PMID: 10911993, Gago-Fuentes et al. PMID: 33379193, Gatz et al. PMID: 21734301)
  - HPO: ventriculomegaly due to aqueductal stenosis

Conclusion

- Ventriculomegaly with aqueductal stenosis
  - Can be isolated or associated with other cerebral/extra-cerebral malformations
  - Several genetic causes, several syndromes

- Foetopathological examination: discriminating clinical/histopathological features
  - Corpus callosum agenesis + adducted thumbs in male fetus: *L1CAM*
  - Ependymal rosettes: *MPDZ* and *CRB2* (with or without cystic kidney disease)
  - Germinolytic cyst = mitochondrial cytopathy: *PDHA1* and *TIMMDC1*

- Next-Generation Sequencing:
  - Whole-exome sequencing, whole-genome sequencing
  - Improved diagnosis rate
  - Foetopathological examination is mandatory to perform a Whole-Genome Sequencing in France (PFMG2025)
  - Evolution over time: *CRB2* gene has been described in ventriculomegaly in 2015
  - New genes will be discovered, new clinical features for already known genes will be described

Necker ENFANTS MALADES HÔPITAL UNIVERSITAIRE

UF, Embryofoetopathologie

Tania Attié-Bitach
Bettina Bessières
Ferechté Encha-Razavi
Laurence Loeuillet
Giulia Petrilli
Nathalie Roux
Houria Salhi
Emmanuel Spaggiari

Zaina Ait Arkoub
Amale Achaiaa
Sophie Chuon
Flavie Frère
Leila Hakkakian
Elodie Lunel
Eglantine Magnin

Fetal Medecine Necker
Yves Ville
Philippe Roth
Laurent Salomon
Julien Stiernemann

Fetal Medecine Port-Royal
François Goffinet
Vassilis Tsatsaris
Mathilde Barrois
Olivia Amsellem



Cytogénétique
MP Beaujard
Valérie Malan
ML Maurin
Serge Romana

Génétique
Julie Steffann
Valérie Cormier-Daire

SoFFœt
Société Française de Fœtopathologie

Aude Tessier
Maryse Bonnières
Jelena Martinovic
Charlotte Mechler
Naima Talhi
Julia Tantau

imagine
INSTITUT DES MALADIES GÉNÉTIQUES

INSERM U1163
Caroline Alby
Lucile Boutaud
Sophie Thomas

Genomique & Bioinformatique
Patrick Nistchke
Christine Bole-Feysot

SeqOIA
LA PLATEFORME GÉNOMIQUE DE PARIS RÉGION

agence de la biomédecine

FONDATION RECHERCHE MÉDICALE